

PATIENT

Tuxedo Suttle

SPECIES

Feline

BREED

DSH

SEX

Male Neutered

AGE

2013

WEIGHT

13.5lbs

INTERPRETED BY

Maggie Machen Lamy,
DVM, DACVIM
(Cardiology)

IMAGING PERFORMED BY

Rebekah Jakum, CVT
ARDMS/RVT

HOSPITAL NAME

The Village
Veterinarian

REFERRING VET

Dr. Longenecker

INVOICE

24128

DATE

5/10/22

PRESENTING CLINICAL SIGNS

History: Feline asthma, grade 3/6 murmur, URI when off of antibiotics, pre anesthesia
Current medications: Flovent 110mcg, Theophylline 50 BID, Pred 2.5 EOD, Gabapentin
Pertinent abnormal PE/Chem/CBC/UA Results: NSF; BNP normal
Idexx consult (4/2022): RSA, mod cardiomegaly, no CHF.

ECHOCARDIOGRAM FINDINGS

2D, m-mode, color flow and doppler imaging is available. The left ventricular wall is normal in dimension. There is a diffusely hyperechoic endocardium consistent with fibrosis. The endocardium also appears remodeled. Borderline LV dilation. Remodeled, mildly hyperechoic papillary muscles. The left atrium is mildly dilated. The right atrium is normal in size. The right ventricle appears normal. Trace TR. The mitral valve is normal in structure and mobility. No MR. Blood flow through the LVOT is normal in velocity. Blood flow through the RVOT is normal in velocity. No PI or AI. No effusions or obvious cardiac tumors identified.

CARDIAC CHART

FELINE CARDIAC PARAMETERS	BODY WEIGHT (kg)	HR (BPM)	IVSd (cm) (Moise, Pipers)	LVIDd (cm) (Moise, Pipers)	LVWd (cm) (Moise, Pipers)	FS (%)	EF (%)
NORMAL PARAMETER	-----	150-240	0.35-0.55	<2 (mean 1.5)	3.5-0.55	35-67	80-100
PATIENT	6.1	120	0.37	1.8	0.37	58	90
FELINE CARDIAC PARAMETERS	LA/AO (Boon)	LA/AO HEART BASE (Swe) (Abbott)	LA 2D short axis Base view (cm) (Abbott)		LVOT VEL (m/s)	RVOT VEL (m/s)	E max (m/s)
NORMAL	<1.5	<1.3	<1.2		<1.6	<1.3	<0.9
PATIENT	NM	1.5	1.5		1.0	0.84	NM

**Note: All measurements based upon multi-modal images and methods. An average value is reported.*
Adapted from June Boon, Veterinary Echocardiography, 1998
Abbott J & MacLean H JVIM 2006;20: 111-119, Moise et al. Am J Vet Res 47:1476, 1986. Pipers et al. Am J Vet Res 40:882, 1979.

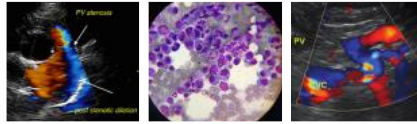
INTERPRETATION OF THE FINDINGS & FURTHER RECOMMENDATIONS

Mild abnormalities are identified, including mild LA dilation and borderline LV changes. No evidence of significant hypertrophy ruling out typical hypertrophic disease. No other significant findings are identified. These abnormalities may suggest early Unclassified/Restrictive Disease (RUCM); however, monitoring for progression is advised.

Anesthetic risk is considered mild, however judicious IV fluid rates are advised to avoid fluid overload. Additionally drugs that stimulate heart rate should be avoided unless clinically necessary (glycopyrrolate, atropine). Avoid vasodilators as this may worsen an outflow obstruction (if present). A reasonable protocol includes opioid/benzodiazepine premedication, propofol induction, isoflurane maintenance. Additionally steroids should be used with caution on older cats, as even a 'normal' geriatric heart can develop evidence of intolerance and fluid retention.

Monitor for any development of clinical signs at home, including labored breathing, cough or signs of a blood clot (paralysis, neurologic change).

No cardiac medications are clearly indicated.



PATIENT

Tuxedo Suttle

A recheck echocardiogram is recommended in 6 months to screen for progressive LA dilation, sooner if any issues arise in the interim.

SPECIES

Feline

BREED

DSH

SEX

Male Neutered

AGE

2013

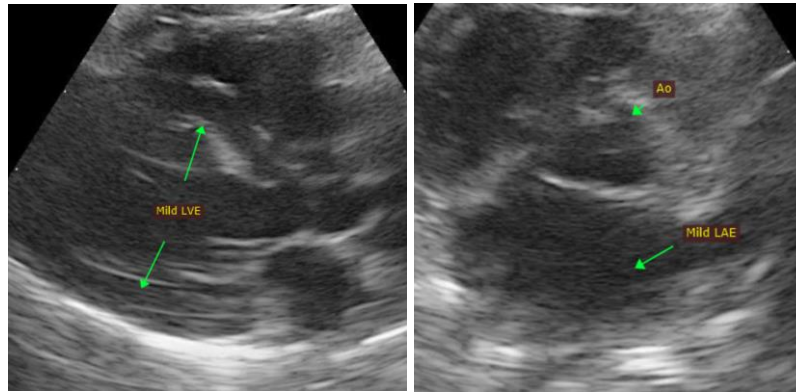
WEIGHT

13.5lbs

INTERPRETED BY

Maggie Machen Lamy,
DVM, DACVIM
(Cardiology)

IMAGES



The information and recommendations provided are based on the images presented by the referring veterinarian. No evaluation can be communicated regarding pathology that was not visible in the image/video clips provided.

Thank you for this referral. If the clinical or image interpretation does not parallel your findings or if I can be of any further assistance, please contact me.

Maggie Machen Lamy, DVM
Diplomate of the American College of Veterinary Internal Medicine (Cardiology)
info@sonopath.com

IMAGING PERFORMED BY

Rebekah Jakum, CVT
ARDMS/RVT

HOSPITAL NAME

The Village
Veterinarian

REFERRING VET

Dr. Longenecker

INVOICE

24128

DATE

5/10/22